

A European Multicenter Study Evaluating the Flex Robotic System in Transoral Robotic Surgery

Stephan Lang, MD; Stefan Mattheis, MD; Pia Hasskamp, MD; Georges Lawson, MD;
Christian Güldner, MD; Magis Mandapathil, MD; Patrick Schuler, MD; Thomas Hoffmann, MD;
Marc Scheithauer, MD; Marc Remacle, MD

Objectives/Hypothesis: To evaluate the application of the Flex Robotic System in transoral robotic surgery (TORS).

Study Design: Multicenter, prospective, open-label, single-armed clinical study.

Methods: A prospective clinical follow-up multicenter study was performed from July 2014 to October 2015 assessing the safety and efficacy of the Medrobotics Flex Robotic System for access and visualization of the oropharynx, hypopharynx, and larynx as well as for resection of benign and malignant lesions. A total of 80 patients were enrolled. Access and visualization of five anatomic subsites (base of tongue, palatine tonsil area, epiglottis, posterior pharyngeal wall, and false vocal cords) were individually graded by the surgeon. Setup times, access and visualization times, surgical results, and adverse events were documented.

Results: The relevant anatomic structures could be exposed and visualized properly in 75 patients, who went on to have a surgical procedure performed with the Flex Robotic System. Access and visualization of the palatine tonsil area, posterior pharyngeal wall, epiglottis, and posterior pharyngeal wall were excellent. However, false vocal cords and vocal cords were more difficult to expose. Seventy-two patients were treated successfully with the Flex Robotic System. There were no serious or unanticipated device-related adverse events caused by the Flex Robotic System.

Conclusions: Lesions in the oropharynx, hypopharynx, and larynx could be successfully resected with the Flex Robotic System, specifically developed for TORS. Our study provides evidence that the Flex Robotic System is a safe and effective tool in TORS.

Key Words: Transoral robotic surgery, flexible, robot, robotic scope, endoscope, head and neck tumors, laser.

Laryngoscope, 00:000-000, 2016

INTRODUCTION

To overcome the morbidity and disadvantages of open surgery, transoral resection of tumors of the head and neck has proven to be an important therapeutic modality.^{1,2} Due to the difficult and narrow anatomy in the pharynx and larynx, as well as the complex functions in swallowing and voice generation, transoral surgery remains challenging.

In this context it could be shown that transoral laser microsurgery (TLM) is an effective tool for the resection of

head and neck tumors. Satisfying oncological results with superior functional outcomes compared to open approaches could be achieved.^{3,4} Limitations result from the need to use rigid endoscopes and laryngoscopes with a narrow channel causing limited vision and exposure, thus making surgical manipulations difficult.

Recently, transoral robotic surgery (TORS) became a valuable new approach in head and neck surgery. To improve the assessment of anatomical regions that are difficult to reach and to visualize the use of rigid three-dimensional (3D) high-definition (HD) angled endoscopes in combination with robotic arms seems to be successful. The most popular robotic system in head and neck surgery is the da Vinci Si HD (Intuitive Surgical, Sunnyvale, CA), used since 2005 to perform transoral resections of head and neck tumors.⁵⁻⁹ The limitations of the system are the rigid and relatively bulky robotic arms, a limited number of cutting devices available, and high costs.¹⁰⁻¹³

Currently available flexible video endoscopes in head and neck surgery are applied for diagnostic endoscopies and taking biopsies. The lack of rigid support and fixation of these instruments makes surgical tumor resection via flexible endoscopes impossible.

The new Flex Robotic System (Medrobotics Corp., Raynham, MA) was specifically developed for head and neck surgery and combines the advantages of a flexible endoscope with a robotic system, which supports flexible instruments and cutting devices for transoral surgery.

From the Department of Otorhinolaryngology–Head and Neck Surgery (S.L., S.M., P.H.), University Hospital Essen, Essen, Germany; Department of Otorhinolaryngology–Head and Neck Surgery (M.R.), Centre Hospitalier de Luxembourg, Luxembourg; Department of Otorhinolaryngology–Head and Neck Surgery (G.L.), University Hospital of Mont-Godinne, Yvoir, Belgium; Department of Otorhinolaryngology–Head and Neck Surgery (C.G., M.M.), University Hospital Marburg, Marburg, Germany; and the Department of Otorhinolaryngology–Head and Neck Surgery (P.S., T.H., M.S.), University Hospital Ulm, Ulm, Germany.

Editor's Note: This Manuscript was accepted for publication September 6, 2016.

Stephan Lang, MD, and Stefan Mattheis, MD, contributed equally (co-first authorship).

The authors have no funding, financial relationships, or conflicts of interest to disclose.

Send correspondence to Stefan Mattheis MD, Assistant Professor, Department of Otorhinolaryngology–Head and Neck Surgery, Universitätsklinikum Essen, Hufelandstrasse 55, 45122 Essen, Germany. E-mail: stefan.mattheis@uk-essen.de

DOI: 10.1002/lary.26358

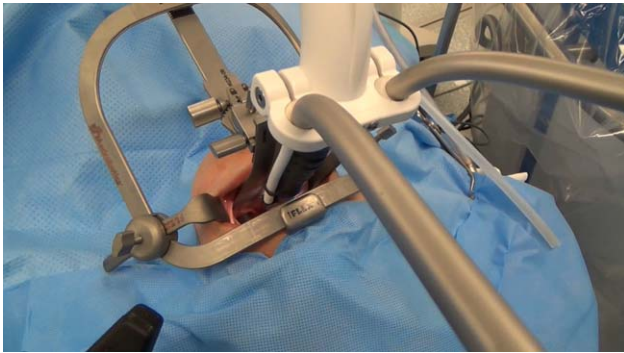


Fig. 1. Transoral insertion of the Flex[®] robotic scope

A flexible robotic scope enables the surgeon to access and visualize structures within the oropharynx, hypopharynx, and larynx. In addition, the system is equipped with two accessory guide tubes for different flexible instruments, providing tactile feedback to the surgeon and different cutting devices (laser fiber holder, monopolar needle knife, monopolar cautery spatula). Reaching from both sides of the robotic scope into the surgical field, those instruments are optically controlled via an HD digital camera, positioned at the distal end of the robotic scope. Upon reaching the anatomy of interest, the robotic scope becomes rigid and serves as a stable platform from which flexible instruments are deployed, visualized, and manipulated.

The system is divided in three different units: the Flex Cart, carrying the Flex base and the Flex scope, the Flex console, and the single-use Flex instruments. The system is small and mobile, and can be placed on either side of the patient. The Flex scope is moved by the surgeon via an HD monitor with the help of a controller on top of the Flex console (Fig. 1).

Illumination of the surgical field is achieved by light-emitting diodes mounted at the tip of the scope.

The camera can be cleaned with an integrated lens washer. Various flexible instruments are inserted through two flexible guide tubes and are placed in the surgical field. The instruments are fixed and supported at the tip of the flexible robotic scope and have articulating end effectors allowing for easy access to the targeted lesions. The surgeon drives the robotic scope and performs surgical procedures via visualization on the Flex console display or on an external HD monitor (Fig. 2).

After successful cadaveric and animal studies, the Flex Robotic System achieved the Conformité Européenne (European Conformity) mark in March 2014 and US Food and Drug Administration clearance in July 2015. The first patients were treated in Europe in June 2014.¹⁴⁻¹⁸

The objective of this study was to assess the safety and efficacy of the Flex Robotic System for transoral robotic head and neck surgery.

MATERIALS AND METHODS

From July 2014 to October 2015, a prospective, single-arm, nonrandomized, postmarket clinical follow-up study, approved by the local ethics committee, was performed at four European sites to assess the safety and efficacy of the Flex Robotic System. The system was used to visualize and access surgical sites in the oropharynx, hypopharynx, and larynx to resect benign as well as malignant lesions or to take biopsies.

A total of 80 patients were enrolled, of whom 79 subjects were treated according to the study protocol. Thirty-four patients were enrolled at the University Hospital of Essen (Germany), 18 at the University Hospital of Louvain (Belgium), 15 at the University Hospital of Marburg (Germany), and 13 at the University Hospital of Ulm (Germany). In one patient, the Flex Robotic System experienced a system failure during start-up, so the investigator did not attempt or perform any procedures on this subject. The remaining 79 patients were comprised of 44 males and 35 females with an average age of 64 years. In 72 patients the surgical procedure was successfully completed with the Flex Robotic System. Thirty-nine (54%) of these patients presented with

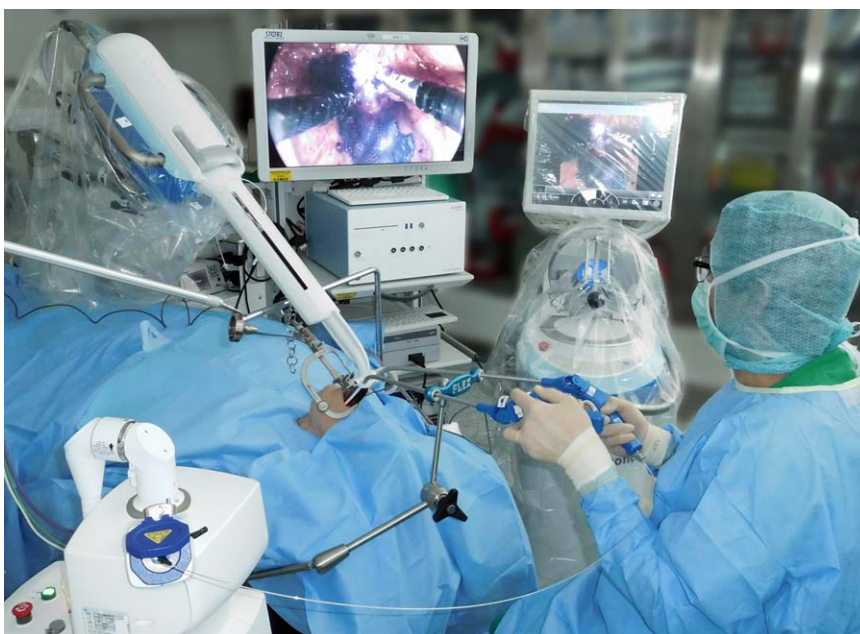

Fig. 2. Flexible instruments with laser fiber inserted in the guide tubes and visualized on the monitor.

TABLE I.

Anatomical Regions Accessed With the Flex Robotic System.	
Oropharyngeal sites of lesions, n = 39	No.
Base of tongue	26
Tonsils	6
Lateral pharyngeal wall	3
Lateral tongue	2
Soft palate	2
Hypopharyngeal sites of lesions, n = 12	
Piriform sinus	9
Lateral and posterior pharyngeal wall	3
Laryngeal sites of lesions, n = 21	
Epiglottis	11
Vocal cords	5
Arytenoid cartilage	3
False vocal cords	2

oropharyngeal, 12 (17%) with hypopharyngeal, and 21 (29%) with laryngeal pathologies (Table I).

In 31 patients, a diagnostic endoscopy followed by a biopsy was carried out. In 41 patients, the total resection of a lesion or tumor was the goal of the surgical procedure.

To open the mouth and to expose the pharynx and larynx the Feyh-Kastenbauer retractor (Gyrus ACMI, Southborough, MA) and the newly designed Flex Retractor (Flex Retractor System; Medrobotics Corp.) were used. Different-shaped blades are available to retract the tongue, base of tongue, and epiglottis to access anatomical areas difficult to reach. In base of tongue, vallecula, or epiglottis procedures, we preferred a transnasal intubation, placing the intubation tube at the posterior pharyngeal wall to achieve a broad exposure. A transoral intubation was performed to resect lesions in the piriform sinus, the arytenoid cartilage, or at the posterior pharyngeal wall, with the intubation tube placed under the spatula blade. To manipulate, pull, and grasp tissue, a fenestrated grasper or Maryland dissector was used. Cutting devices available were a flexible CO₂ laser fiber (Lumenis AcuPulse DUO; Lumenis Ltd., Yokneam, Israel), a monopolar needle knife, or a monopolar cautery spatula. A tube integrated in the Flex retractor blades and connected to an external suction device ensured smoke evacuation. Additional smoke and blood evacuation was performed with an external suction tube operated by an assisting surgeon.

The device setup time, the time for the access and visualization process, and surgical time were documented. The access and visualization process included the insertion of the Flex scope and the exposure and visualization of the palatine tonsil, posterior pharyngeal wall, base of tongue, epiglottis, and false vocal cords. The surgeon graded the quality of visualization and access to the relevant anatomical regions on a scale from 5 to 1 (5 = no difficulty present, 1 = unable to perform).

Surgical results as well as possible adverse events and malfunctions were documented intraoperatively. Patients were examined on postoperative day 1 and day 2 for possible adverse events.

RESULTS

In 31 patients a diagnostic endoscopy followed by a biopsy was performed; in 41 patients the targeted lesion or tumor was totally resected. Surgical access and visualization of the lesions was possible in 75 patients (95%).

The following attempted surgical procedure with the Flex Robotic System was considered successful in 72 (91.1%) patients. Seven procedures were converted to other means of surgical treatment, in most cases TLM.

In three cases the vocal cords could not be visualized and accessed due to a narrow anatomy and the lack of longer blades of the utilized retractor. In one case a full access to the false vocal cords could not be achieved due to a hypertrophy of the base of tongue in combination with a narrow anatomy and a large hyoid bone. In one case the resection of a tumor of the lateral oropharyngeal wall led to moderate bleeding. The Flex procedure had to be interrupted because hemostasis could only be achieved by using rigid instruments.

In two cases a motor malfunction of the Flex Scope led to an insufficient exposure of the targeted lesions and the procedures had to be converted to TLM.

In the vast majority of cases, lesions and tumors in the oropharynx, hypopharynx, and larynx could be accessed with good exposure (Fig. 3). In 75 patients (95%) access and visualization was graded 4 or 5 points out of 5 (no difficulty present) by the surgeon. The overall rating for access and visualization was 4.5 out of 5.

The setup of the system was quick and could be managed by the nurses easily. The average setup time was 11.2 minutes, demonstrating a learning curve with a setup time under 10 minutes in the last 10 patients. The mean surgical procedure time was 41 minutes (range, 5-131 minutes).

Hemostasis was achieved by using flexible monopolar cautery via the spatula or the Maryland dissector. In addition, transoral rigid monopolar suction cautery or endoscopic clips were applied. In one patient the surgeon was unable to control a moderate bleeding using the Flex Robotic System. The system was removed and hemostasis was achieved with standard instruments.

Surgeons experienced some minor device malfunctions that did not impact the surgical outcome or cause an injury to the subject. In 12 cases slight lags in motion were observed while manipulating the instruments, especially at the end of longer procedures. In one case the Flex Robotic System experienced a system failure during start-up and the surgeon did not attempt to perform any procedures on the subject.

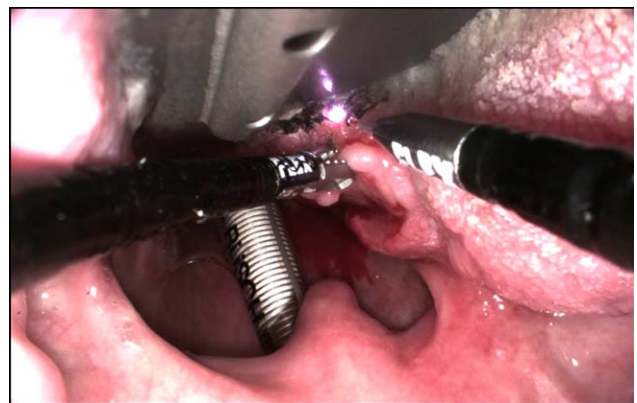


Fig. 3. Resection of a base of tongue tumor with a CO₂-laser fiber.

In 10 patients, superficial mucosal lesions in the oropharynx and at the lips occurred while introducing the retractor and the Flex scope. In six patients we observed a localized postoperative edema of the pharynx causing a prolonged intubation for 3 days in one patient. In two patients a postoperative nasogastric feeding tube was necessary due to dysphagia. These patients underwent tumor resections, and the relation of the adverse events to the robotic surgery remains unclear, because mucosal edema is also a common side effect of standard transoral procedures. No serious or unanticipated adverse events occurred.

DISCUSSION

For more than a decade TORS in head and neck cancer was performed using the da Vinci Si System, yielding a superior surgical outcome with a lower incidence of side effects as compared to open surgery. In the same time an increased rate of transoral surgical treatment of head and neck tumors in comparison to open approaches could be observed.²⁰ With respect to TLM, the da Vinci System offers the advantage of a better overview and wristed instruments. However, even experienced surgeons face limitations when using established techniques such as TLM or the da Vinci System in TORS.²¹ In 2013, Moore and Hinni stated: "Transoral laser surgery for base of tongue tumors is challenging. It requires specific training, patience and hard-earned experience, and it does not translate to the talents or personality of every head and neck surgeon."²² The same holds true for TORS, and we completely agree that performing oncologic resections requires well-experienced surgeons to achieve excellent oncological outcomes.

In 2014, a new innovation entered the market: The Flex Robotic System, which was specifically developed to fulfill the needs of a head and neck surgeon. This is in direct contrast to the da Vinci Si, which was originally constructed for large cavity surgery. By doing so, the Flex Robotic System offers an operator-controlled, flexible robotic scope that gives excellent access to the oropharyngeal and most laryngeal regions. In combination with the Flex retractor, the integrated HD camera provides an overview and exposure of all relevant anatomical structures of the pharynx and larynx. However, in some cases a higher camera resolution and a better contrast are desirable.

In comparison to the da Vinci system, the Flex Robotic System is highly mobile, and the components are easy to handle. This is advantageous when the system is used in different surgery rooms and has to be transported. Due to the easy handling we also experienced short setup times of <10 minutes in the last 30 cases.

Exposure of the oropharynx, hypopharynx, and supraglottic larynx was quick, and the instruments were easily controlled and visualized by the surgeons using the monitor. Under certain circumstances, especially during longer-lasting surgeries, surgeons noticed slight lags in motion while manipulating the instruments. In addition, a higher applicable force while grasping tissue would be beneficial. On the other hand, the tactile feedback provided by the

instruments was favorable, enabling the surgeon to control the force applied to the tissue. Different flexible instruments are available, allowing a seamless and rapid exchange of instruments during surgery. The applied flexible CO₂ laser fiber as well as the monopolar needle knife allow resections in different angles and not only in the line of sight, for example at the posterior aspect of a tumor mass. The CO₂ laser as a cutting tool in TORS features both superior cutting and coagulation properties and leads to precise resections in combination with good hemostasis.^{23–25} The spot size of the laser is smallest when the tip is guided close and parallel to the tissue, which can be achieved easily with the flexible laser holder. The application of the needle knife allows proper cutting of mucosa, soft tissue, and muscles.

Intraoperative hemorrhage can be challenging in transoral robotic surgery, and different hemostatic techniques should be available.^{26,27} In our study we used the monopolar cautery applied via the needle knife, the cautery spatula, or the Maryland dissector. In addition, rigid cautery suction, inserted transorally beside the Flex scope, was helpful. Large vessels had to be clipped with an additional endoscopic clip applier. The development of system-integrated flexible bipolar cautery tools and an integrated clip applier would be beneficial.

The endolarynx can be exposed and visualized with the Flex Robotic System, but despite being smaller than the da Vinci System, in some rare incidents the end effectors of the instruments are still too long to achieve adequate triangulation for precise resection of smaller lesions inside the larynx. A further development and miniaturization of the instruments and the inauguration of longer and slender laryngeal retractor blades will expand the variety of procedures that can be performed for TORS in the larynx in the future.

The Flex Robotic System has already shown some important advantages, which include it being more mobile than the da Vinci System, allowing a fast and simple setup, and the instruments are easy to handle and provide tactile feedback. The flexible robotic scope provides a good overview of all relevant anatomic structures. 3D camera systems and 4K resolution are common future challenges and prospects in endoscopic surgery and will also be relevant in endoscopic robotic surgery.

CONCLUSION

The Flex Robotic System was specifically developed for TORS and demonstrates great potential as a surgical tool in head and neck surgery. The combination of a robot-assisted flexible robotic scope and flexible instruments allows excellent visualization, maneuverability, and tactile feedback. Lesions, especially in areas difficult to reach, such as the base of the tongue, hypopharynx, or supraglottic larynx, were successfully resected, thus making the system a safe and effective tool in transoral robotic surgery.

BIBLIOGRAPHY

1. Silver CE, Beitler JB, Shaha AR, Rinaldo A, Ferlito A. Current trends in initial management of laryngeal cancer: the declining use of open surgery. *Eur Arch Otorhinolaryngol* 2009;266:1333–1352.

2. Takes RP, Silver CE, Bradley PJ, et al.; International Head and Neck Scientific Group. Current trends in initial management of hypopharyngeal cancer: the declining use of open surgery. *Head Neck* 2012;34:270–281.
3. Steiner W. Results of curative laser microsurgery of laryngeal carcinomas. *Am J Otolaryngol* 1993;14:116–121.
4. Ambrosch P. The role of laser microsurgery in the treatment of laryngeal cancer. *Curr Opin Otolaryngol Head Neck Surg* 2007;15:82–88.
5. Hockstein NG, Nolan JP, O'Malley BW Jr, Woo YJ. Robotic microlaryngeal surgery: a technical feasibility study using the da Vinci surgical robot and an airway mannequin. *Laryngoscope* 2005;115:780–785.
6. McLeod IK, Melder PC. Da Vinci robot-assisted excision of a vallecular cyst: a case report. *Ear Nose Throat J* 2005;84:170–172.
7. O'Malley BW Jr, Weinstein GS, Snyder W, Hockstein NG. Transoral robotic surgery (TORS) for base of tongue neoplasms. *Laryngoscope* 2006;116:1465–1472.
8. Weinstein GS, O'Malley BW Jr, Snyder W, Hockstein NG. Transoral robotic surgery: supraglottic partial laryngectomy. *Ann Otol Rhinol Laryngol* 2007;116:19–23.
9. de Almeida JR, Li R, Magnuson JS, et al. Oncologic outcomes after transoral robotic surgery: a multi-institutional study. *JAMA Otolaryngol Head Neck Surg* 2015;141:1043–1051.
10. Mattheis S, Mandapathil M, Rothmeier N, Lang S, Dominas N, Hoffmann TK. Transoral robotic surgery for head and neck tumors: a series of 17 patients. *Laryngorhinootologie* 2012;91:768–773.
11. Hoffmann TK, Schuler PJ, Bankfalvi A, et al. Comparative analysis of resection tools suited for transoral robot-assisted surgery. *Eur Arch Otorhinolaryngol* 2014;271:1207–1213.
12. Dombrière M, Crott R, Lawson G, Janne P, Castiaux A, Krug B. Cost comparison of open approach, transoral laser microsurgery and transoral robotic surgery for partial and total laryngectomies. *Eur Arch Otolaryngol* 2014;271:2825–2834.
13. Transoral robotic surgery: a review of clinical and cost-effectiveness. CADTH Rapid Response Reports website. Available at: <https://www.cadth.ca/transoral-robotic-surgery-review-clinical-and-cost-effectiveness>. Published January 12, 2015. Accessed February 16, 2016.
14. Johnson PJ, Rivera Serrano CM, Castro M, et al. Demonstration of transoral surgery in cadaveric specimens with the Medrobotics Flex System. *Laryngoscope* 2013;123:1168–1172.
15. Rivera-Serrano CM, Johnson P, Zubiate B, et al. A transoral highly flexible robot: novel technology and application. *Laryngoscope* 2012;122:1067–1071.
16. Mattheis S, Lang S. A new flexible endoscopy-system for the transoral resection of head and neck tumors. *Laryngorhinootologie* 2015;94:25–28.
17. Mandapathil M, Greene B, Wilhelm T. Transoral surgery using a novel single-port flexible endoscope system. *Eur Arch Otorhinolaryngol* 2015;272:2451–2456.
18. Remacle M, M N Prasad V, Lawson G, Plisson L, Bachy V, Van der Vorst S. Transoral robotic surgery with the Medrobotics Flex System: first surgical application on humans. *Eur Arch Otolaryngol* 2015;272:1451–1455.
19. Hasskamp P, Lang S, Holtmann L, Stuck BA, Mattheis S. First use of a new retractor in transoral robotic surgery (TORS). *Eur Arch Otorhinolaryngol* 2016;273:1913–1917.
20. Liederbach E, Lewis CM, Yao K, et al. A contemporary analysis of surgical trends in the treatment of squamous cell carcinoma of the oropharynx from 1998 to 2012: a report from the national cancer database. *Ann Surg Oncol* 2015;22:4422–4431.
21. Weinstein GS, O'Malley BW Jr, Rinaldo A, Silver CE, Werner JA, Ferlito A. Understanding contraindications for transoral robotic surgery (TORS) for oropharyngeal cancer. *Eur Arch Otorhinolaryngol* 2015;272:1551–1552.
22. Moore EJ, Hinni ML. Critical review: transoral laser microsurgery and robot-assisted surgery for oropharynx cancer including human papillomavirus-related cancer. *Int J Radiat Oncol Biol Phys* 2013;85:1163–1167.
23. Desai S, Sung CK, Jang DW, Genden EM. Transoral robotic surgery using a carbon dioxide flexible laser for tumors of the upper aerodigestive tract. *Laryngoscope* 2008;118:2187–2189.
24. Mattheis S, Hoffmann TK, Schuler PJ, Dominas N, Bankfalvi A, Lang S. The use of a flexible CO₂-laser fiber in transoral robotic surgery (TORS). *Laryngorhinootologie* 2014;93:95–99.
25. Remacle M, Matar N, Lawson G, Bachy V, Delos M, Nollevaux MC. Combining a new CO₂ laser wave guide with transoral robotic surgery: a feasibility study on four patients with malignant tumors. *Eur Arch Otorhinolaryngol* 2014;269:1833–1837.
26. Crawford JA, Baghat AY, White HN, Magnuson JS. Hemostatic options for transoral robotic surgery of the pharynx and base of tongue. *Otolaryngol Clin North Am* 2016;49:715–725.
27. Mandal R, Duvurri U, Ferris RL, Kaffenberger TM, Choby GW, Kim S. Analysis of post-transoral robotic-assisted surgery hemorrhage: frequency, outcomes, and prevention. *Head Neck* 2016;38(suppl 1):E776–E782.